njretina®
An affiliate of PRISM Vision Group
October // 2022 // njretina.com

Use of Pegcetacoplan in the treatment of geographic atrophy (GA)

Overview

Geographic atrophy (GA) is a late presentation of dry, age-related macular degeneration (AMD). It is characterized by loss of retinal pigment epithelium, photoreceptors, and choriocapillaris (Image 1)[1]. In the US, it affects nearly 1 million people and accounts for roughly a quarter of the cases of legal blindness[2]. Vision loss related to GA leads to difficulties with reading, driving, and quality of life. Although patients may retain good visual acuity, in areas of geographic atrophy, patients may experience parafoveal scotomas as well as other functional abnormalities including decreased contrast sensitivity function[3]. Geographic atrophy is common in patients with neovascular (wet) AMD and other forms of late AMD, and unfortunately may continue to progress despite ongoing anti-VEGF injections for the treatment of wet AMD. At this point, in October of 2022, there are no FDA approved therapies for the treatment of geographic atrophy.

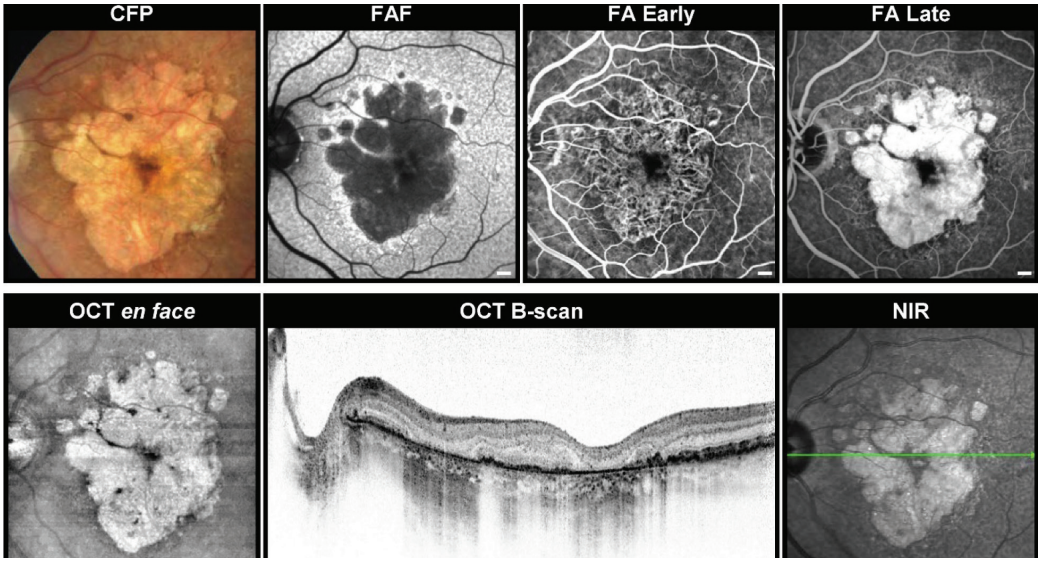

Figure 1: Multimodal imaging of geographic atrophy (GA). Example images of GA from 1 eye using color fundus photography (CFP), fundus autofluorescence (FAF), fluorescein angiography (FA), near-infrared reflectance (NIR), and spectral-domain OCT. Scale bars = 500μm.[10]

Complement system

The complement system is a series of pathways which helps in both innate and adaptive immunity. Through a number of various proteins and effector molecules, it contributes to immune surveillance, inflammation and homeostasis via 3 different activation pathways – the classical, alternative, and lectin pathways (See Image 2)[4]. Under normal conditions, this system is tightly regulated so that host cells do not become damaged (and so that exogenous cells, such as bacteria, or infected cells, can become removed). Genetic variants of one of these molecules, C3, is strongly associated with an increased risk of exudative and atrophic forms of AMD[5]. Byproducts of this cascade have been found in elevated levels in plasma and drusen in patients with AMD[6].

Targeting the complement system to affect geographic atrophy pathogenesis

Prior clinical trial programs have attempted to target the complement system, notably lampalizumab, a monoclonal antibody binding to complement factor D. This molecule failed to reach its primary endpoint in reducing GA lesion area compared to sham in the phase III CHROMA and SPECTRI studies[7].

Currently under investigation is an inhibitor of C3, pegcetacoplan. The clinical trials investigating pegcetacoplan have divided the dosing schedule to either monthly, or every-other-month (EOM)-dosing in 15 milligram doses in the form of an intravitreal injection with 0.1mL of liquid. The Phase II FILLY study had demonstrated that monthly and EOM dosing of pegcetacoplan demonstrated a 29% and 20% respective decrease in growth of the square-root GA-area compared to controls at month 12 (Image 3)[8]. Currently, the Phase III trials DERBY and OAKS are underway. The 24-month data for DERBY and OAKS were released by the manufacturer in August of 2022, demonstrating a 19% and 22% reduction in GA lesion growth compared to sham in each of the respective trials on a monthly regimen (Image 4).

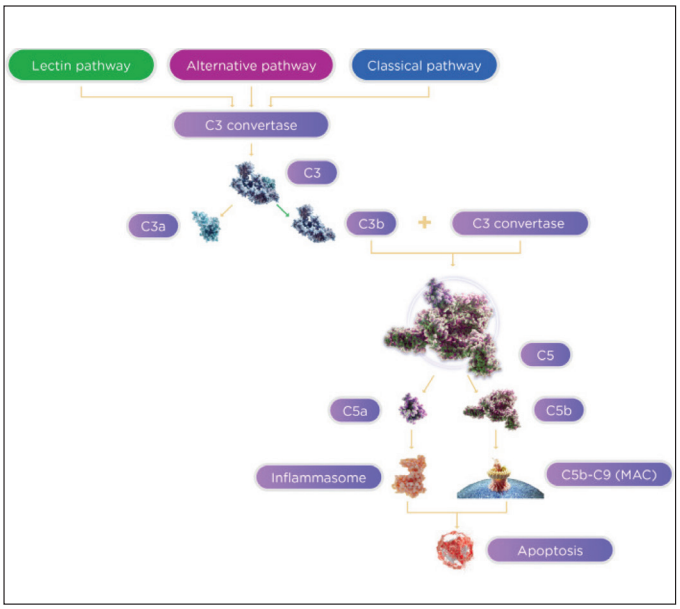

Figure 2: Desai D, Dugel PU. Complement cascade inhibition in geographic atrophy: a review. Eye (Lond). 2022;36(2):294-302. doi:10.1038/s41433-021-01765-x

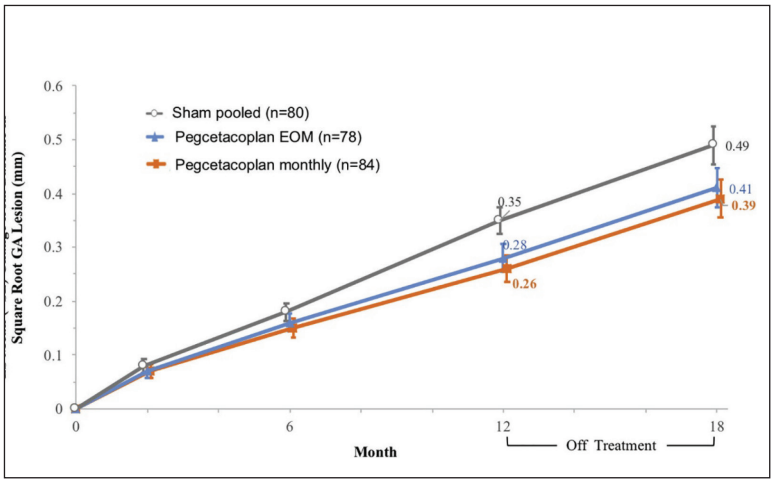

Figure 3: 8-month results from the Phase II FILLY study demonstrating reduced progression of GA lesion size when treated with Pegcetacoplan[8]

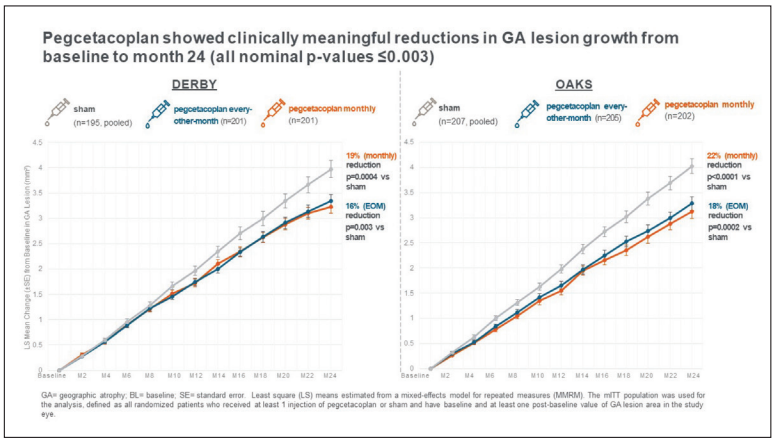

Figure 4: Monthly injection of pegcetacoplan demonstrated a 19% reduction in GA lesion size growth in the DERBY study and 22% reduction in OAKS, while every-other-month injections yielded a 16% and 18% reduction in each study respectively.[11]

Adverse events

Adverse events noted with pegcetacoplan included those with typical intravitreal injections, such as endophthalmitis and elevations in intraocular pressure. In the phase II FILLY program, however, there were noted increased rates of exudation and development of neovascular AMD in eyes treated monthly or EOM pegcetacoplan compared to sham (20.9% (18/86) monthly and 8.9% (7/79) EOM compared to1.2% (1/81) in the sham arm). Eyes that developed neovascular activity were then concomitantly treated with anti-VEGF and overall did not alter the visual acuity. Patients continued to receive pegcetacoplan per study protocol with anti-VEGF injections if exudation were present. In the ongoing Phase III trials at 18 months, rates of exudation were 11.7% (24/206) in DERBY and 7.5% (16/213) in OAKS in the monthly treated arms, and 5.3% (11/208) and 7.1% (15/212) in the EOM-treatment arms in the respective studies. The 24-month data regarding exudation will be presented at the American Academy of Ophthalmology in 2022.

Implications on care for our patients

Similar to how anti-VEGF therapy had revolutionized the way we treat neovascular AMD and other disease processes, with the possible upcoming approval of pegcetacoplan, there will be a paradigm shift in how we treat geographic atrophy. As of October 2022, the drug has been submitted to the Food and Drug Administration for review and is currently under Priority Review with a potential answer for approval in November 2022. Several points are important to emphasize regarding treating patients with geographic atrophy. First, not all dry AMD is geographic atrophy. The presence of drusenoid deposits without the loss of RPE or photoreceptors is not the type of patient enrolled in these trials. Therefore, any use of this drug in patients without pre-existing geographic atrophy would not be indicated and would be considered off-label.

Second, we know that advanced AMD (development of center-involving geographic atrophy or wet AMD) can develop in patients with less-advanced forms of AMD. As we know from the AREDS study regarding the natural history of dry macular degeneration, patients with intermediate sized drusen (defined as drusen between 60-124 microns in size) have a 4% rate of developing advanced AMD in 10 years (Image 5). Those with large drusen (>125 microns) or RPE abnormalities have a 21% chance of developing advanced AMD in 10 years and a 50% chance if both large drusen and RPE abnormalities are present. Patients who have been monitored with large drusen or RPE changes would benefit from earlier referral to a retina physician for evaluation and possible treatment given the high rate of developing geographic atrophy or wet AMD.

Ideal patients to treat with pegcetacoplan would be those with significant progression of GA on serial imaging. Patients with non-central GA would also benefit from treatment with pegcetacoplan to help reduce the amount of atrophy that may grow. As newer medicines become released, this will certainly be the start, and not the end, of treating a once untreatable disease.

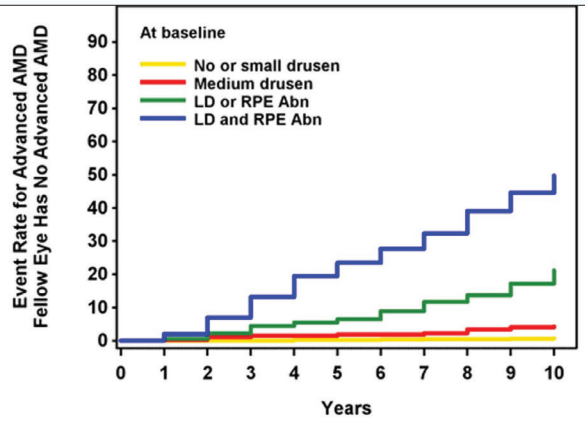

Event Rate for Advanced AMD by Year

	N	1	2	3	4	5	6	7	8	9	10
No or small drusen	1604	0.0	0.1	0.1	0.3	0.3	0.4	0.5	0.5	0.6	0.7
Medium drusen	662	0.3	1.1	1.5	1.5	1.9	1.9	2.2	3.4	4.0	4.3
LD or RPE Abn	894	0.6	2.2	4.4	5.5	6.4	8.9	11.7	13.6	17.2	21.2
LD and RPE Abn	648	2.0	7.0	13.2	19.5	23.5	27.7	32.3	39.1	44.6	49.7

Figure 5: Event rates for development of advanced AMD (center-involving GA or wet AMD) stratified by baseline fundus findings.[9]

References:

1. Holz FG, Strauss EC, Schmitz-Valckenberg S, van Lookeren Campagne M. Geographic Atrophy: Clinical Features and Potential Therapeutic Approaches. Ophthalmology. 2014;121(5):1079-1091. doi:10.1016/j.ophtha.2013.11.023
2. Chakravarthy U, Bailey CC, Johnston RL, et al. Characterizing Disease Burden and Progression of Geographic Atrophy Secondary to Age-Related Macular Degeneration. Ophthalmology. 2018;125(6):842-849. doi:10.1016/j.ophtha.2017.11.036
3. Sunness JS, Rubin GS, Applegate CA, et al. Visual Function Abnormalities and Prognosis in Eyes with Age-related Geographic Atrophy of the Macula and Good Visual Acuity. Ophthalmology. 1997;104(10):1677-1691. doi:10.1016/S0161-6420(97)30079-7
4. Kolev M, Friec GL, Kemper C. Complement — tapping into new sites and effector systems. Nat Rev Immunol. 2014;14(12):811-820. doi:10.1038/nri3761
5. Yates JRW, Sepp T, Matharu BK, et al. Complement C3 Variant and the Risk of Age-Related Macular Degeneration. New England Journal of Medicine. 2007;357(6):553-561. doi:10.1056/NEJMoa072618
6. Schaft TL van der, Mooy CM, Bruijn WC de, Jong PT de. Early stages of age-related macular degeneration: an immunofluorescence and electron microscopy study. British Journal of Ophthalmology. 1993;77(10):657-661. doi:10.1136/bjo.77.10.657
7. Holz FG, Sadda SR, Busbee B, et al. Efficacy and Safety of Lampalizumab for Geographic Atrophy Due to Age-Related Macular Degeneration: Chroma and Spectri Phase 3 Randomized Clinical Trials. JAMA Ophthalmology. 2018;136(6):666-677. doi:10.1001/jamaophthalmol.2018.1544
8. Liao DS, Grossi FV, Mehdi DE, et al. Complement C3 Inhibitor Pegcetacoplan for Geographic Atrophy Secondary to Age-Related Macular Degeneration: A Randomized Phase 2 Trial. Ophthalmology. 2020;127(2):186-195. doi:10.1016/j.ophtha.2019.07.011
9. Chew EY, Clemons TE, Agrón E, et al. Ten-Year Follow-up of Age-Related Macular Degeneration in the Age-Related Eye Disease Study: AREDS Report No. 36. JAMA Ophthalmology. 2014;132(3):272-277. doi:10.1001/jamaophthalmol.2013.6636
10. Fleckenstein M, Mitchell P, Freund KB, et al. The Progression of Geographic Atrophy Secondary to Age-Related Macular Degeneration. Ophthalmology. 2018;125(3):369-390. doi:10.1016/j.ophtha.2017.08.038
11. Apellis Announces 24-Month Results Showing Increased Effects Over Time with Pegcetacoplan in Phase 3 DERBY and OAKS Studies in Geographic Atrophy (GA) | Apellis Pharmaceuticals, Inc. Accessed September 23, 2022. https://investors.apellis.com/news-releases/news-release-details/apellis-announces-24-month-results-showing-increased-effects

At the forefront of clinical research

NJRetina continuously conducts clinical trials at key locations. Our clinical research coordinators will be happy to discuss the inclusion/exclusion criteria or any other aspect of these studies with you or your patients. If you have any questions, please feel free to contact:

Joseph Portelli - Teaneck: 201-837-7300, jportelli@njretina.com
Zoe Etuke - Teaneck: 201-837-7300, zetuke@njretina.com
Kerowyn Smith - Teaneck: 201-837-7300, KSmith@njretina.com
Dina Christodoro - Toms River: 732-797-3984 and Edison: 732-906-1887, dchristodoro@njretina.com
Andy Merino - Toms River: 732-797-3984 and Edison: 732-906-1887, amerino@njretina.com

Enrolling Studies:

Wet AMD

Edison

Opthea Coast: A Phase 3, Multicenter, Double-masked, Randomized Study to Evaluate the Efficacy and Safety of Intravitreal OPT-302 in Combination with Aflibercept, Compared with Aflibercept Alone, in Participants with Neovascular Age-related Macular Degeneration (nAMD)

Toms River

Opthea Shore: A Phase 3, Multicenter, Double-masked, Randomized Study to Evaluate the Efficacy and Safety of Intravitreal OPT-302 in Combination with Ranibizumab, Compared with Ranibizumab Alone, in Participants with Neovascular Age-related Macular Degeneration (nAMD)

Teaneck

Elevatum: A Phase IIIB/IV, Multicenter, Open-Label, Single-Arm Study to investigate Faricimab treatment in response to treatment-naïve, underrepresented patients with Diabetic Macular Edema.

Teaneck

Luna: A Multi-Center, Randomized, Double-Masked Phase 2 Study to Assess Safety and Efficacy of ADVM-022 (AAV.7m8-aflibercept) in Anti-VEGF Treatment Experienced Patients with Neovascular (Wet) Age[1]related Macular Degeneration

Diabetic Retinopathy

Teaneck

Ocuterra: A Phase 2 Randomized, Double-Masked, Vehicle[1] Controlled, Multicenter Study to Evaluate the Safety and Efficacy of OTT166 Ophthalmic Solution in the Treatment of Diabetic Retinopathy (DR)

Upcoming Studies:

Wet AMD

Teaneck

Eye Point: A Phase 2, Multicenter, Prospective, Randomized, Double-Masked, Parallel Study of EYP-1901, a Tyrosine Kinase Inhibitor (TKI), Compared to Aflibercept in Subjects with Wet AMD

GA / Dry AMD

Teaneck

Alexion: A Phase 2, Double-Masked, Placebo-Controlled, Dose Range Finding Study of Danicopan (ALXN2040) in Patients with Geographic Atrophy (GA) Secondary to Age-Related Macular Degeneration (AMD)

Janssen: Phase 2/3, Randomized, Double-masked, Multicenter, Dose-ranging, Sham[1]Controlled Clinical Trial to Evaluate Intravitreal JNJ-81201887 (AAVCAGsCD59) Compared to Sham Procedure for the Treatment of Geographic Atrophy (GA) Secondary to Age-related Macular Degeneration

RVO

Teaneck, Toms River, Edison

Bayer Study: A Randomized, Double-Masked, Active-Controlled, Phase 3 Study of the Efficacy and Safety of Aflibercept 8 mg With Macula Edema due to Retinal Vein Occlusion

To read past issues of our newsletter, visit njretina.com.